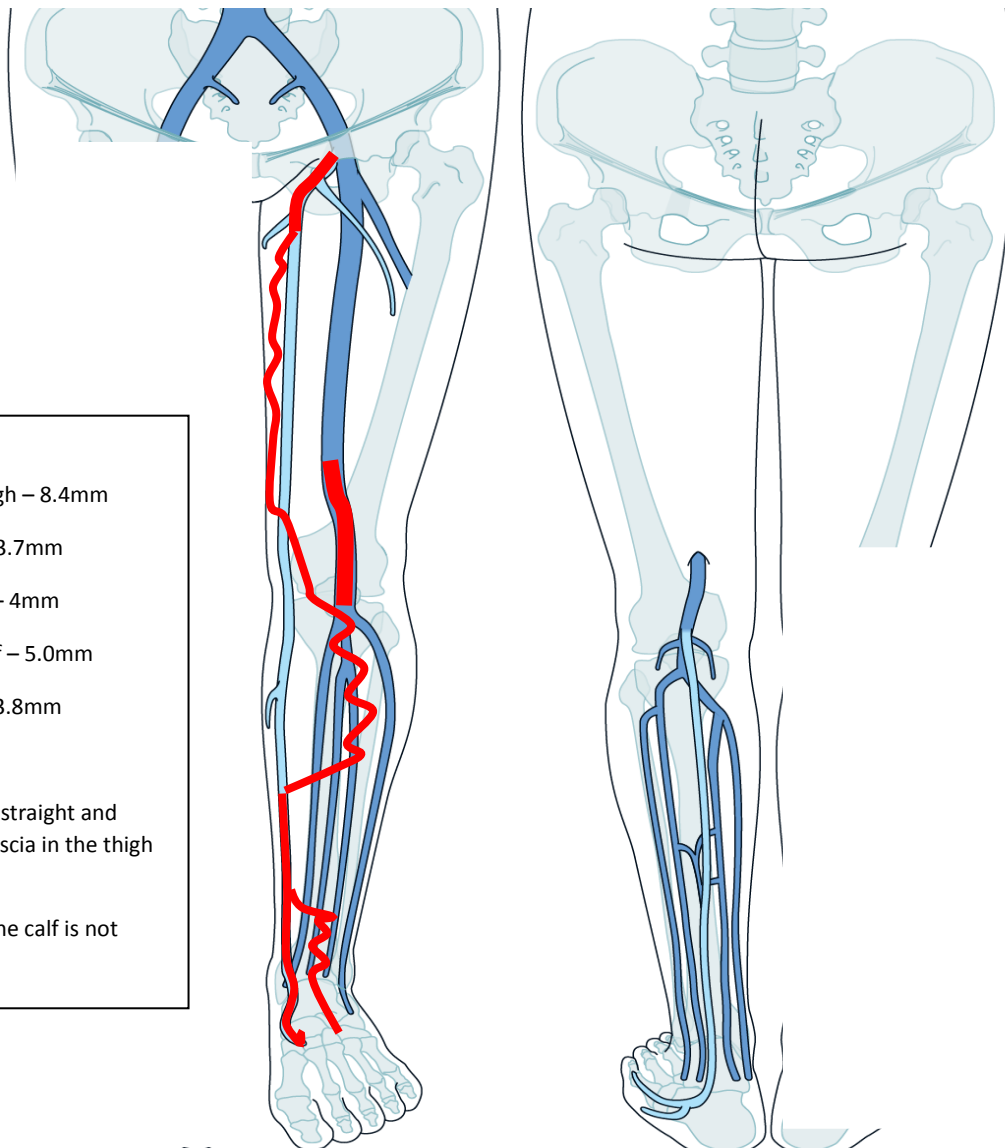


### Vascular lab report

Assessed by: Suleman Choudhury

Anterior view

Posterior view



#### Left GSV:

Proximal thigh – 8.4mm

Mid-thigh – 3.7mm

Distal thigh – 4mm

Proximal calf – 5.0mm

Distal calf – 3.8mm

The GSV lies straight and within the fascia in the thigh only.

The GSV in the calf is not straight.



red colour denotes reflux



Competent superficial vein



Competent deep vein



Deep vein scarring

---

**US Doppler lower limb veins Lt:**

The Sapheno-Femoral Junction (SFJ) and Greater Saphenous vein (GSV) are patent and incompetent. The GSV fills a varicose vein (4.2mm) 3cm distal to the SFJ. The varicose vein courses laterally across the knee and then medially to reflux into the mid-calf GSV. The mid-calf GSV fills a varicose vein which courses to the foot.

The Sapheno-Popliteal Junction (SPJ) and Short Saphenous vein (SSV) are patent and competent.

The distal femoral and popliteal vein are patent and incompetent. All other deep veins are patent and competent.

No incompetent perforators detected.

---

---